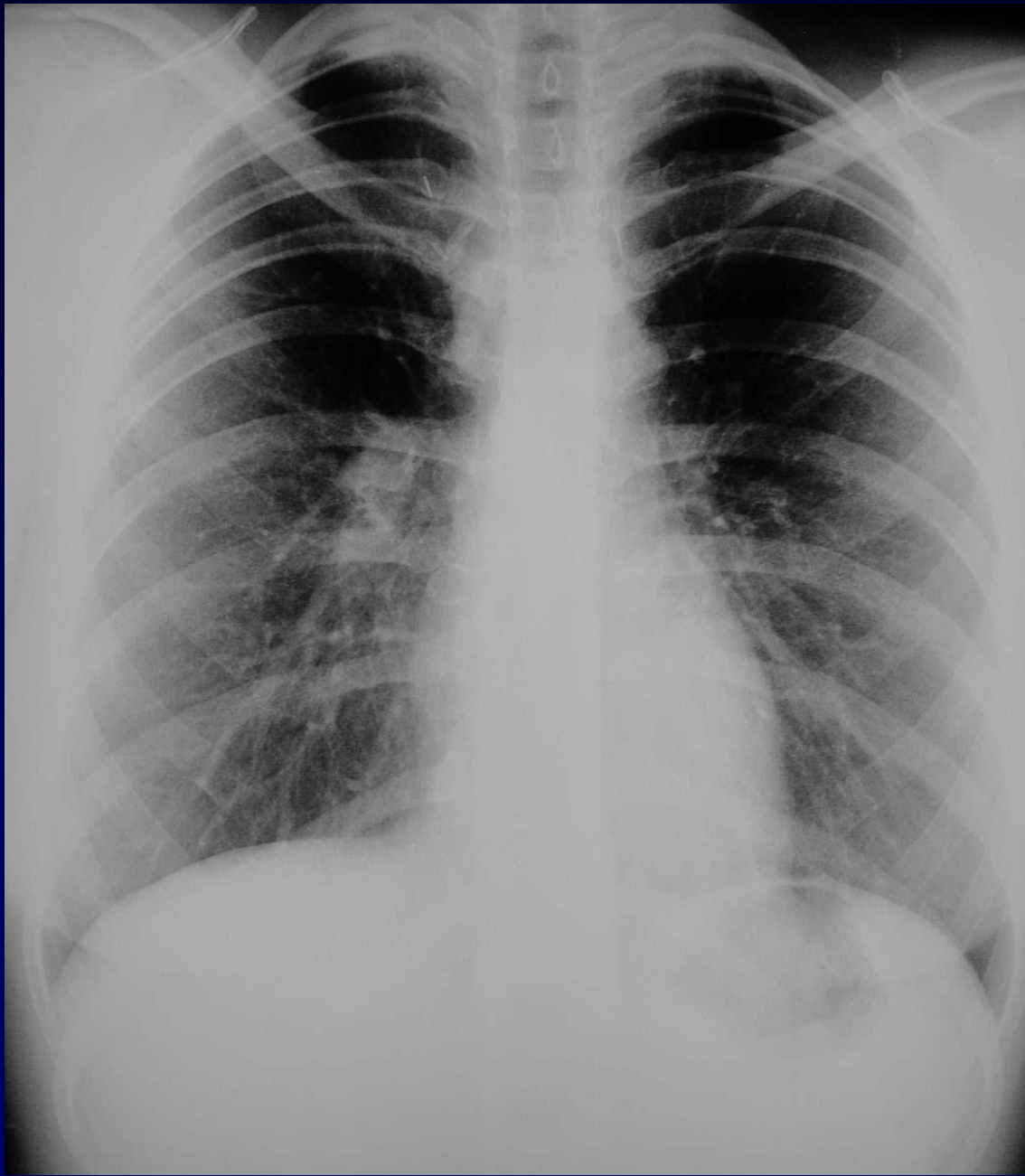


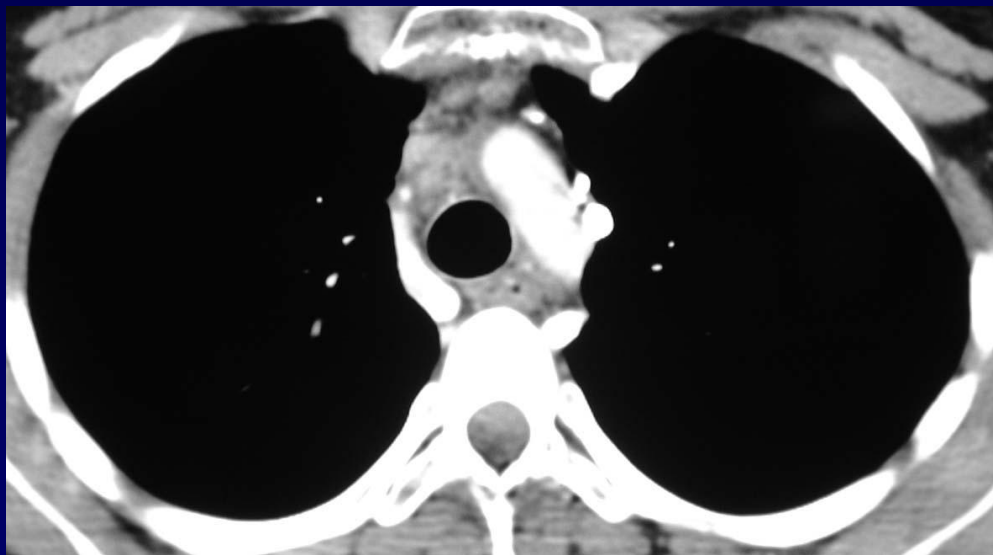
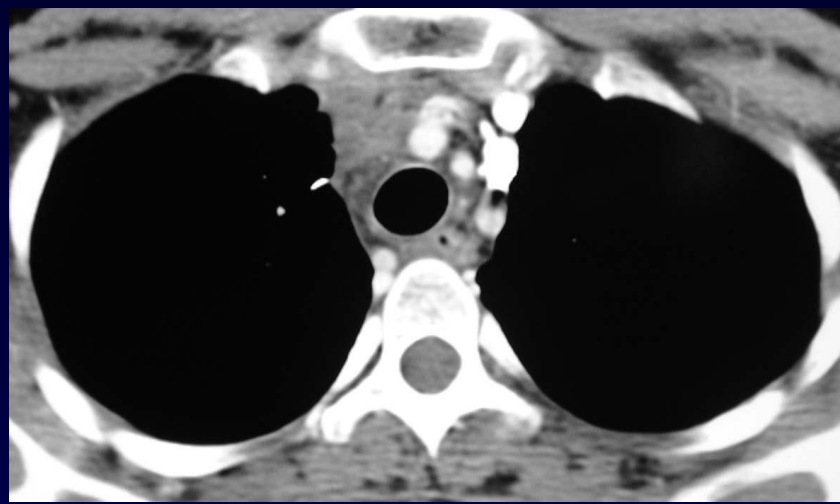
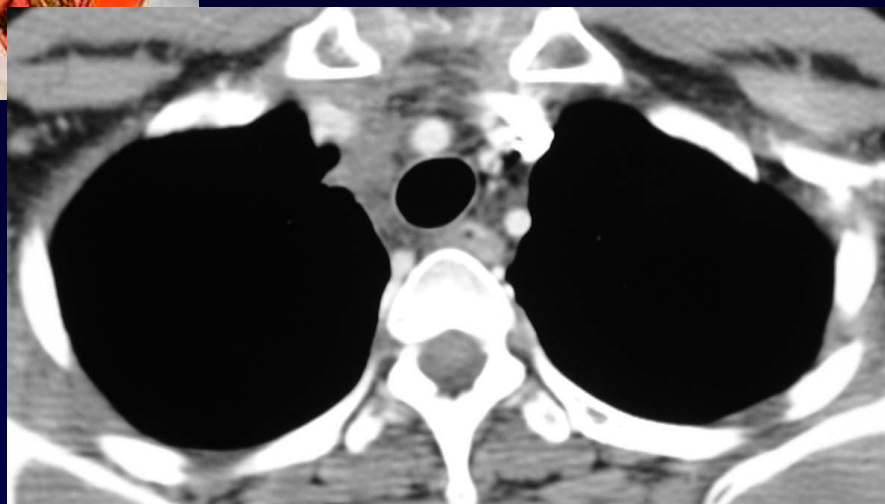


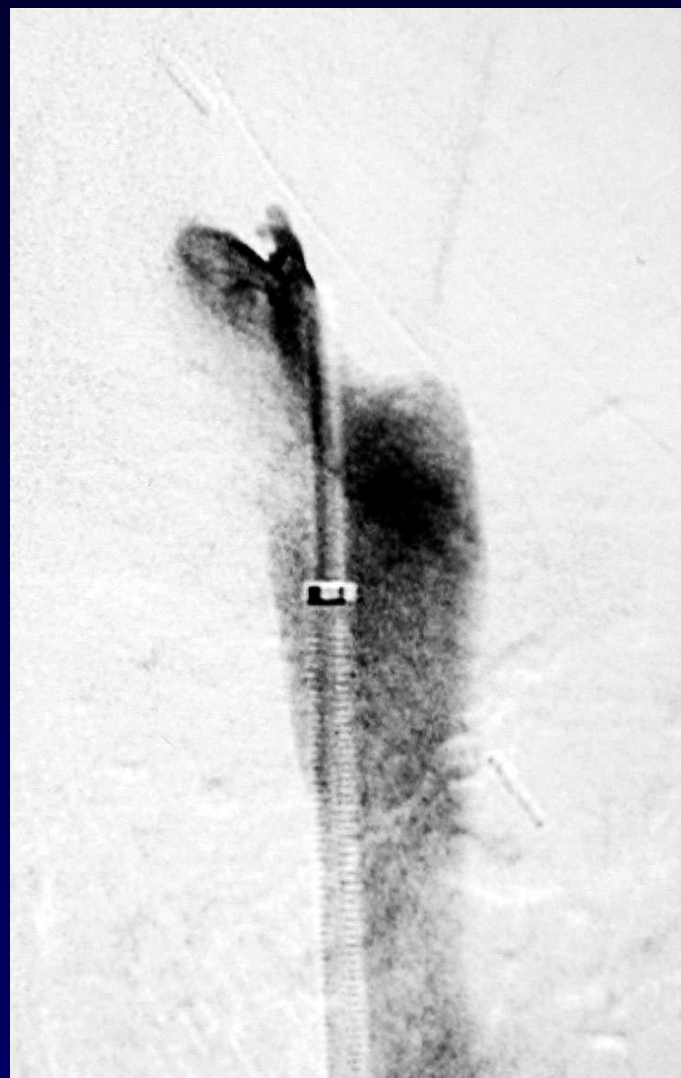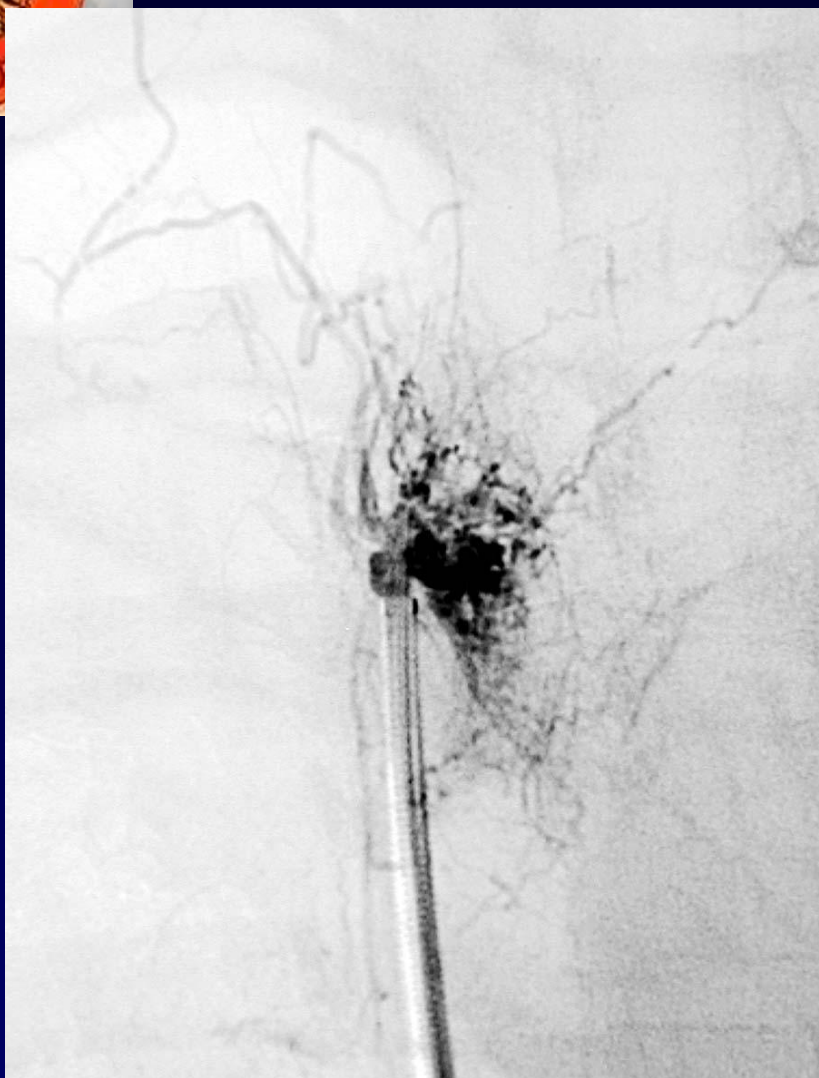
P. LACOMBE

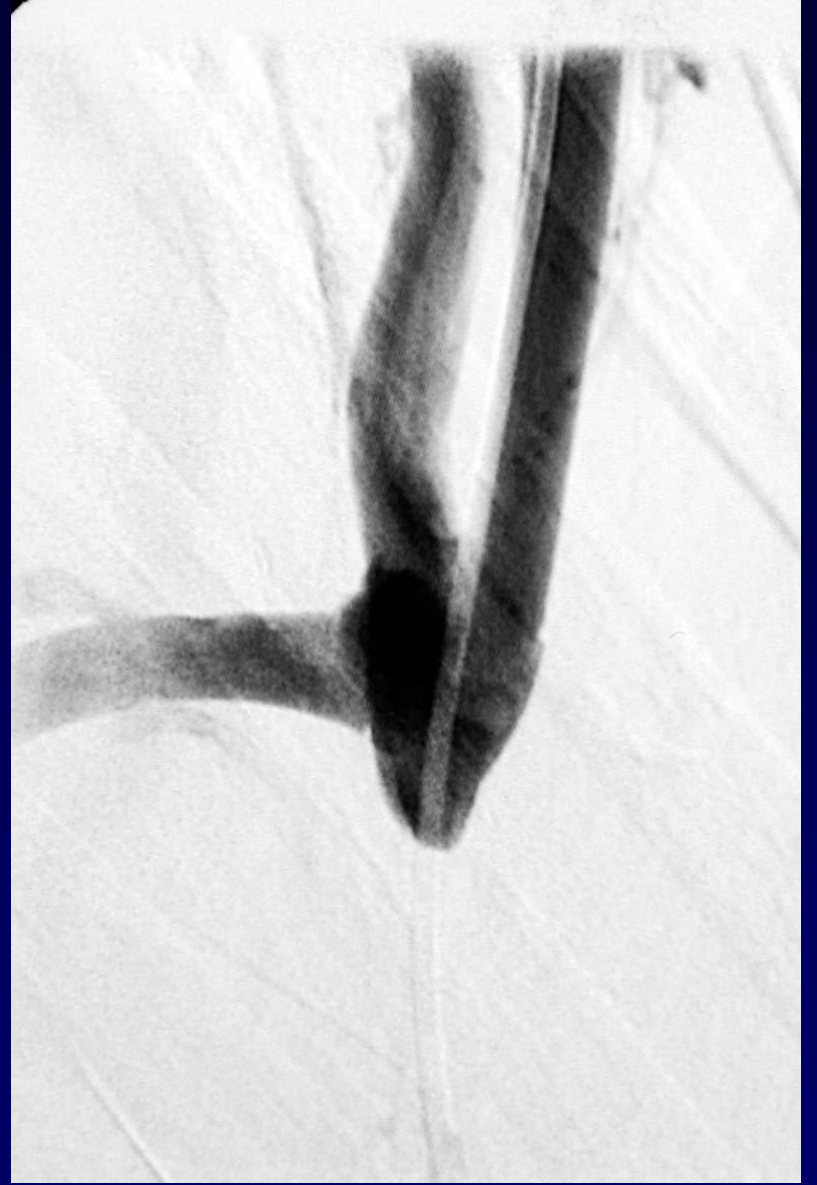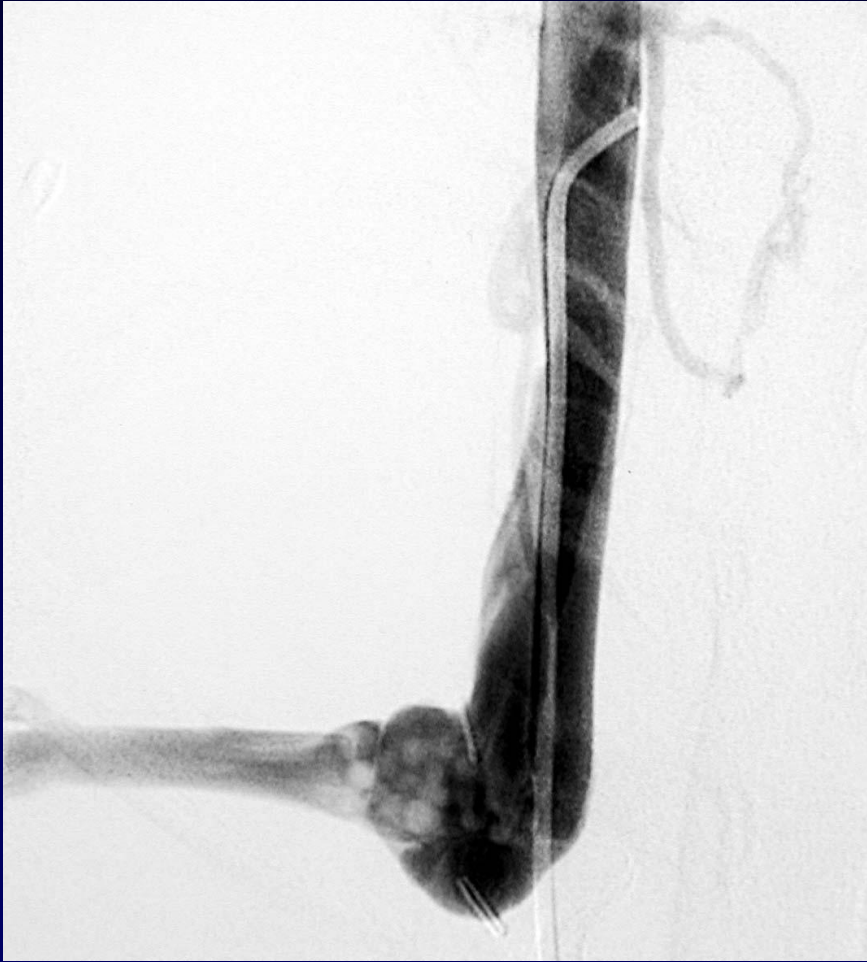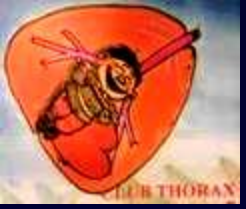Femme de 19 ans

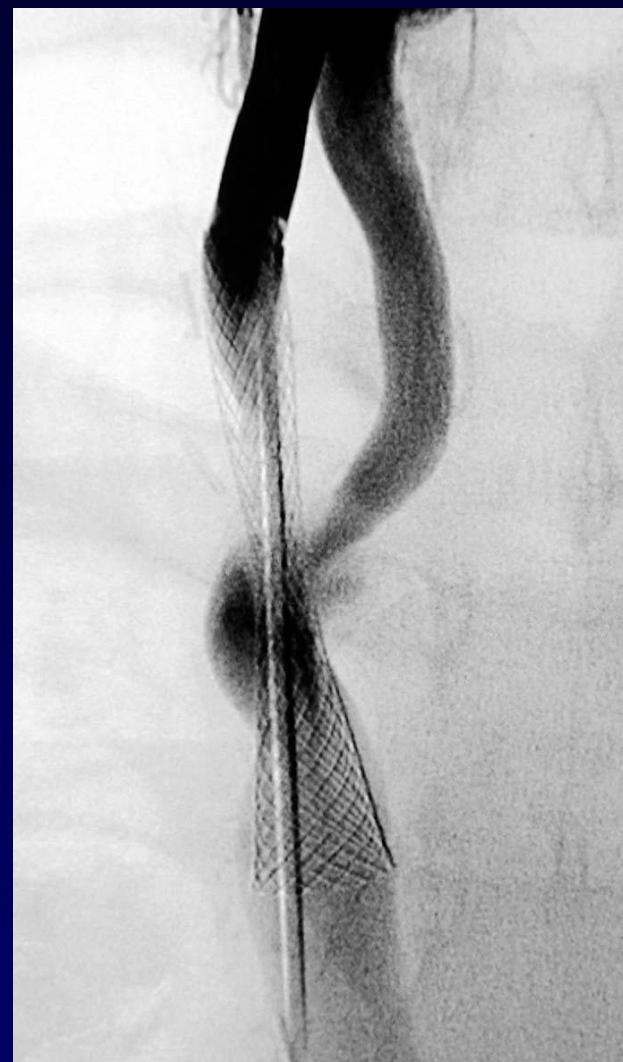
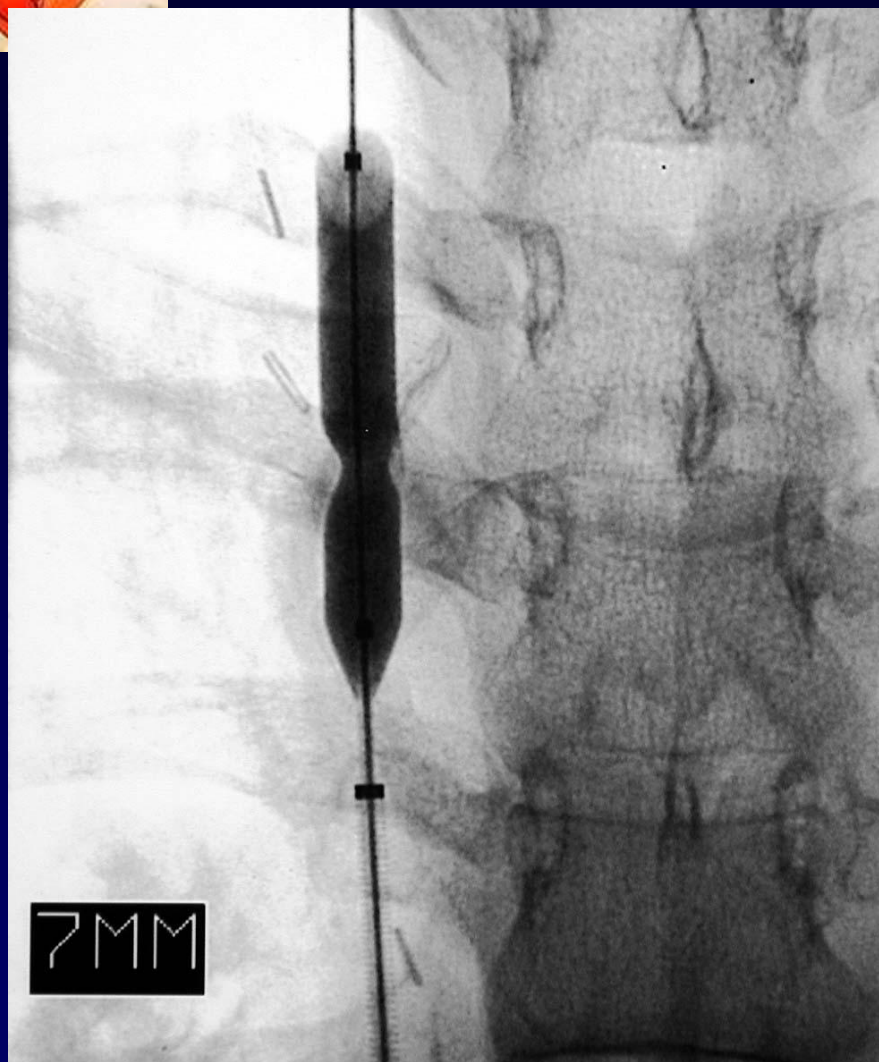Syndrome cave supérieur chez une patiente aux antécédents de maladie de Hodgkin traitée par chimio- et radiothérapie.

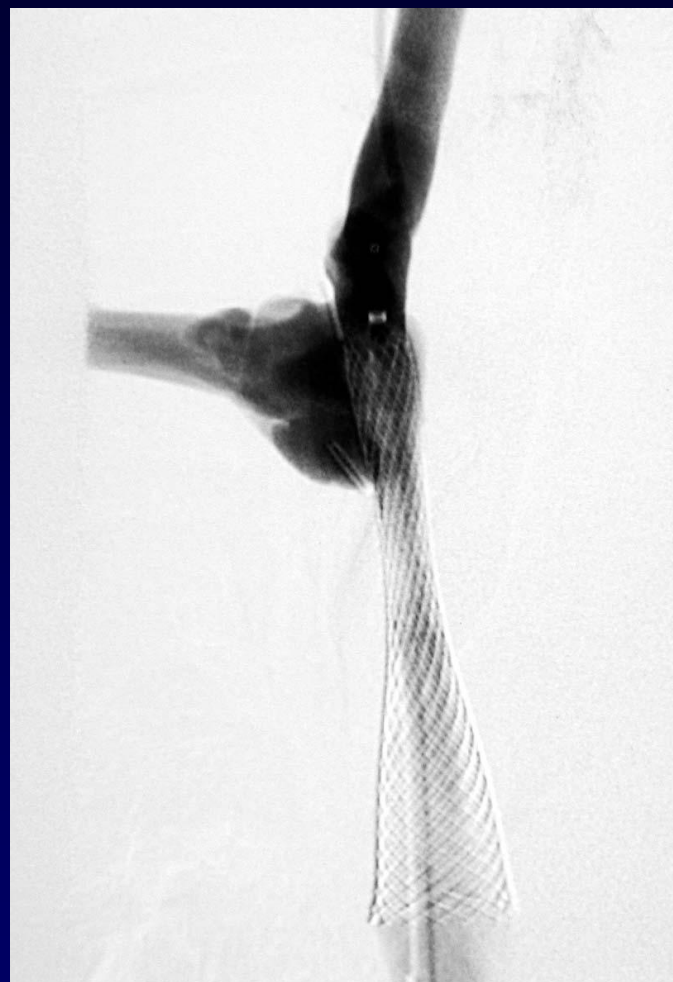
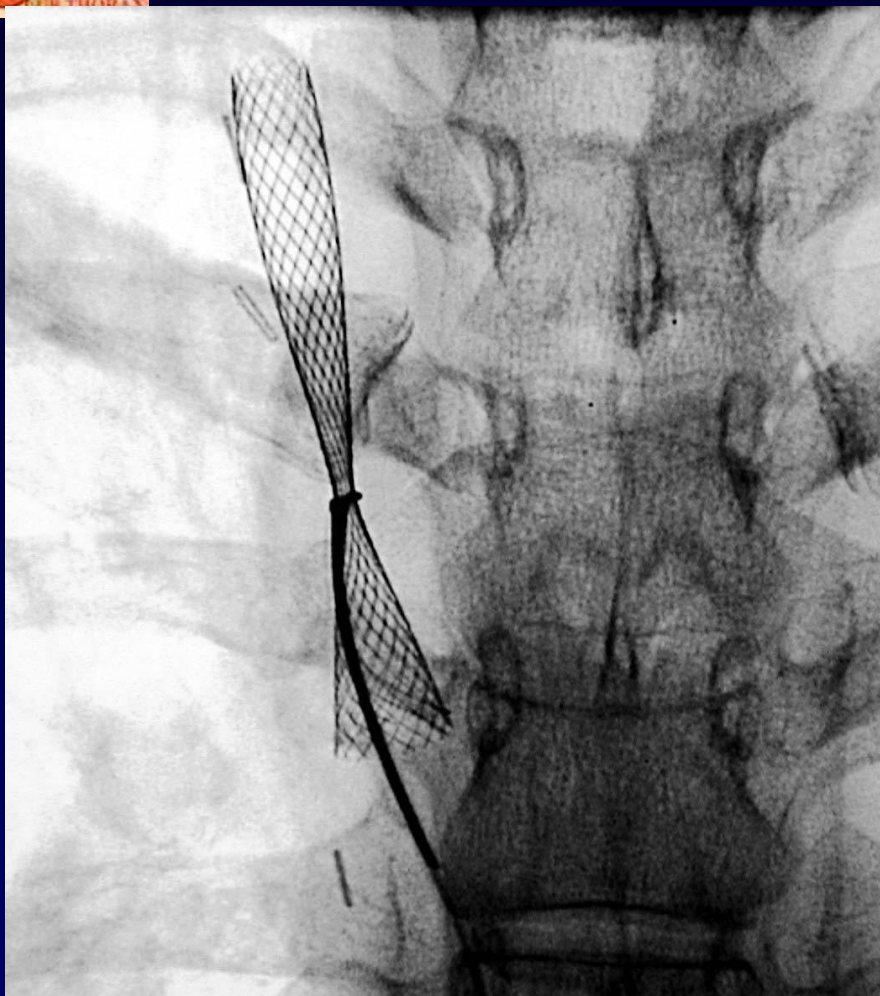


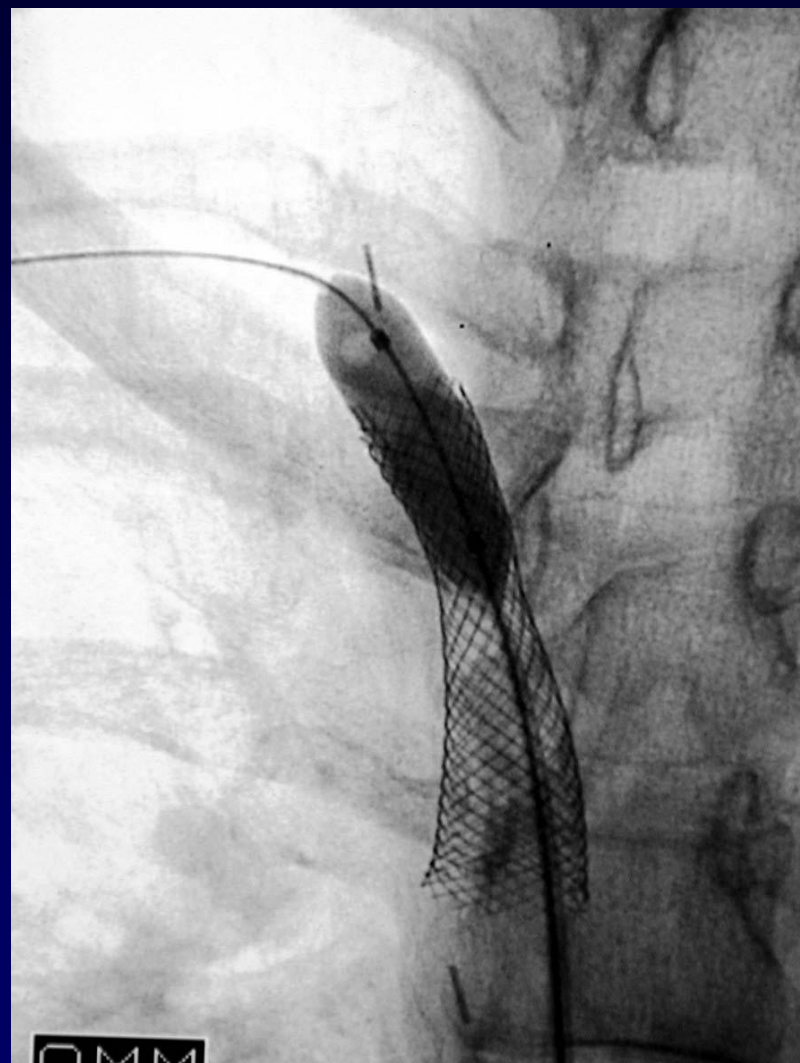
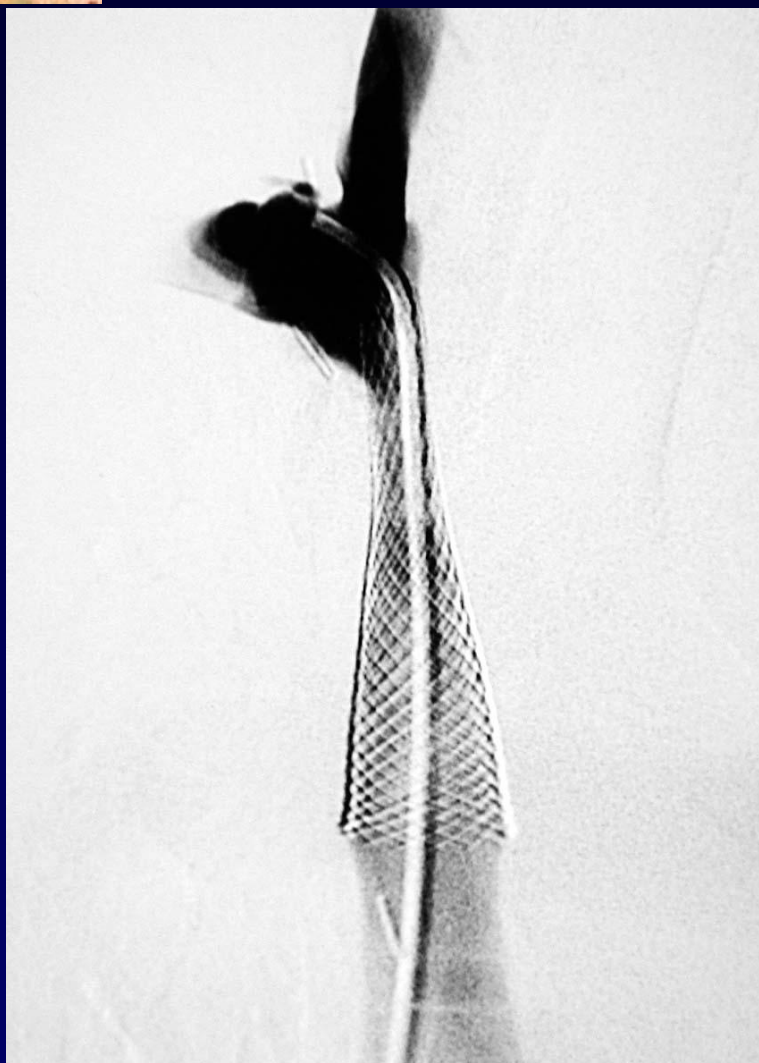
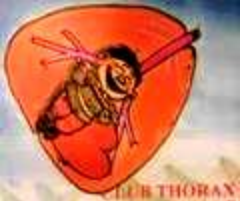







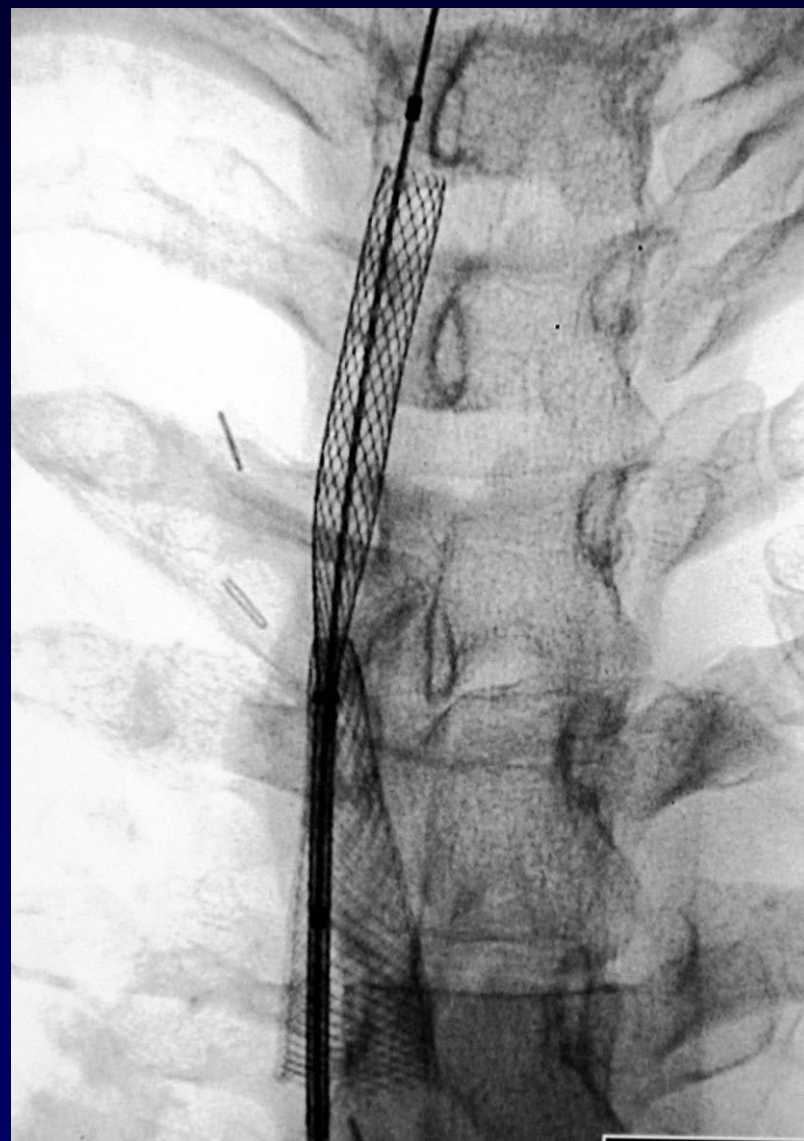
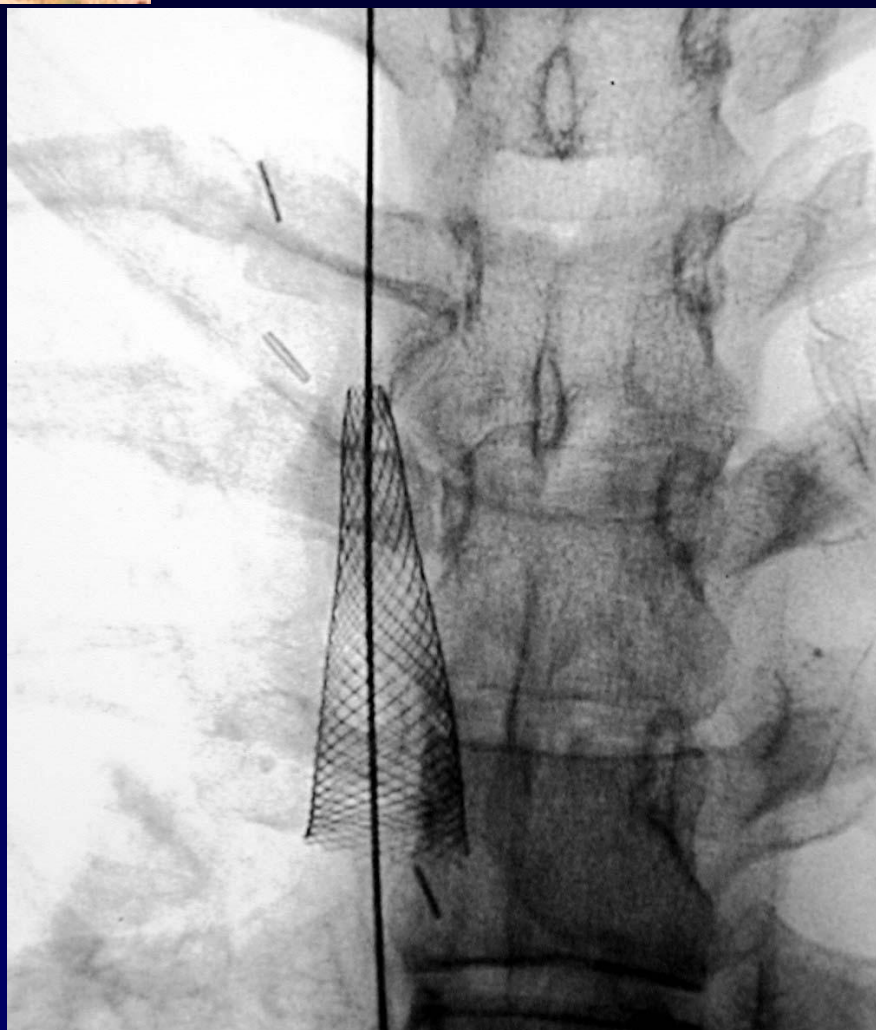


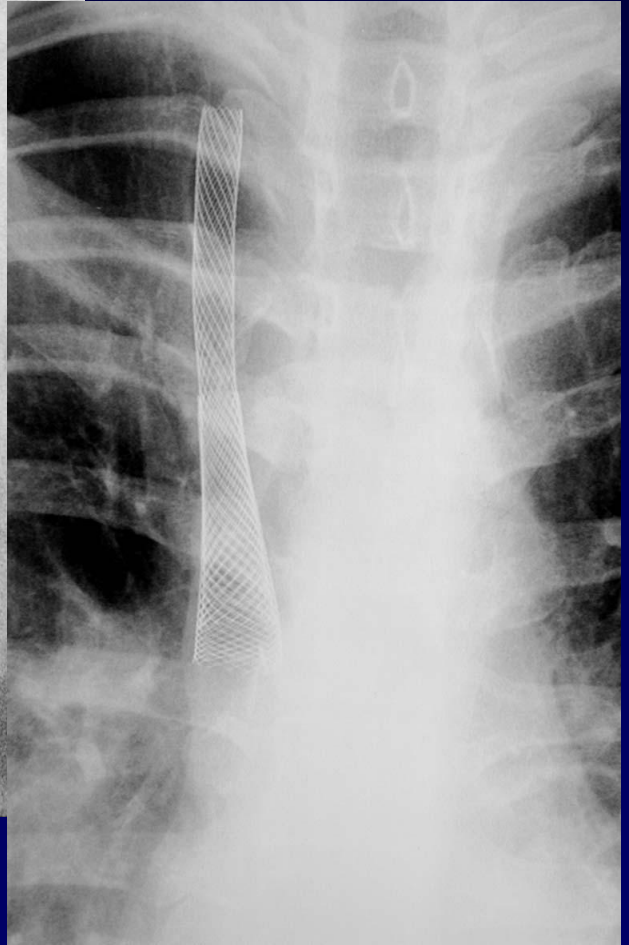
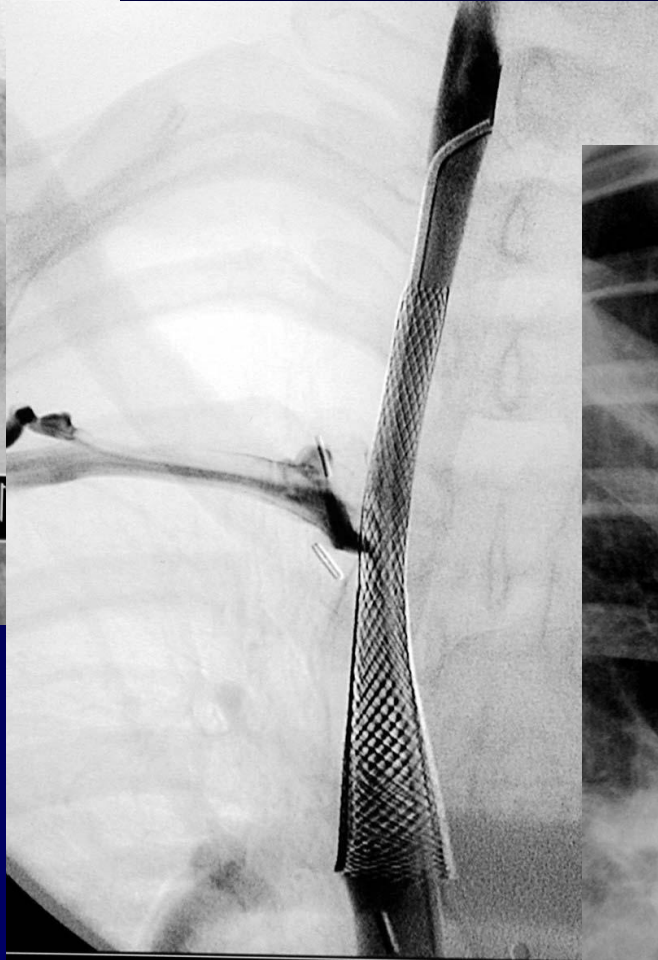
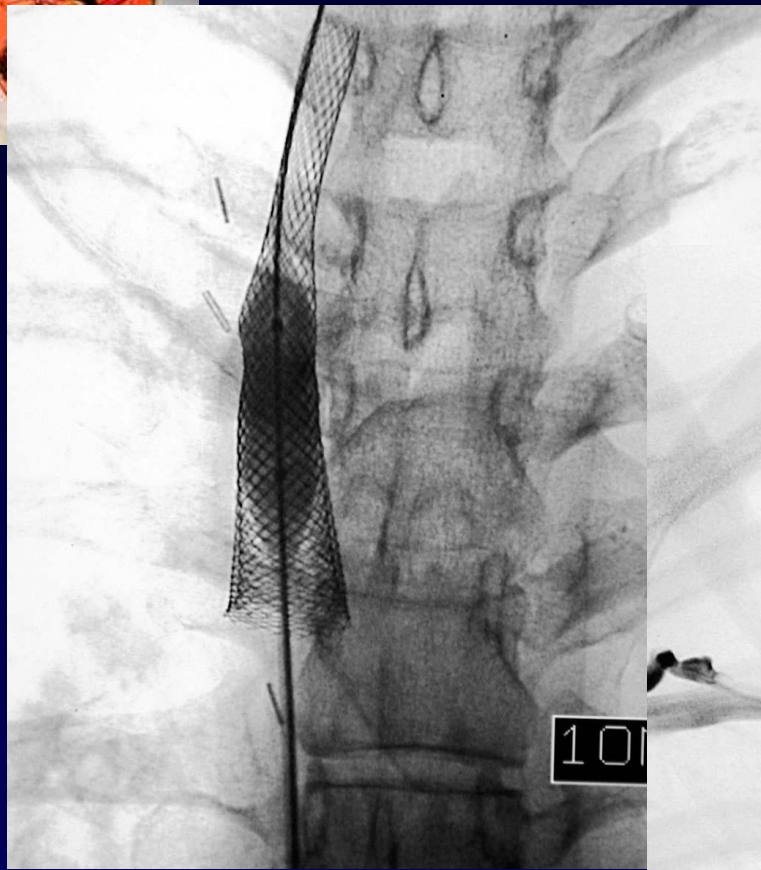




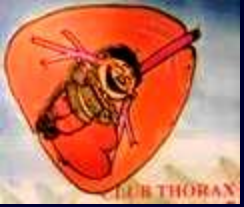RECUPERATION DU BALLON ROMPU









Mise en place d'une prothèse cave supérieure